

A Periclitoral Mass as a Cause of Persistent Genital Arousal Disorder

Sarah Bedell, BA,* Andrew Todd Goldstein, MD,[†] and Lara Burrows, MD, MSc[†]

*New York University School of Medicine, New York, NY, USA; [†]Center for Vulvovaginal Disorders, Washington, DC, USA

DOI: 10.1111/jsm.12165

ABSTRACT

Introduction. Persistent genital arousal disorder (PGAD) is an intrusive and unremitting disorder for which several possible etiologies and treatments have been suggested.

Aim. To describe a woman who developed PGAD in association with a periclitoral mass, a potential physical cause of the disorder that has not been previously described in the medical literature.

Methods. A postmenopausal woman presented with 6 months of persistent, unrelenting genital arousal and clitoral pain that was unrelated to sexual stimuli. Careful examination revealed a tender, firm, mobile, left-sided mass that appeared to compress the dorsal nerve of the clitoris.

Results. Complete excision of the mass resulted in full resolution of her symptoms over several weeks.

Conclusion. Localized causes of persistent genital arousal, though rare, should be included in the differential diagnosis PGAD as detection and treatment can lead to a complete recovery. **Bedell S, Goldstein AT, and Burrows L. A periclitoral mass as a cause of persistent genital arousal disorder. J Sex Med 2014;11:136-139.**

Key Words. Persistent Genital Arousal Disorder; Periclitoral Mass; Clitoral Pain; Papillary Hidradenoma; PGAD

Introduction

Persistent genital arousal disorder (PGAD) is defined as spontaneous, intrusive, and unwanted genital arousal that occurs in the absence of sexual desire or stimulation. Any awareness of subjective arousal is typically but not invariably unpleasant. Arousal is unrelieved by one or more orgasms or sexual activity, and the feelings of arousal may persist for hours or days [1]. Because the etiology and pathophysiology have not been fully elucidated, much of what is known about PGAD is the result of multiple case reports and limited systemic research. Proposed etiologies include vascular, neurological, pharmacological, and psychological [2-4]. Regarding vascular causes, an increased incidence of pelvic varices has been found in women that meet criteria for PGAD

compared with that of the general population [3,5]. Waldinger et al. used magnetic resonance imaging (MRI) technology to localize varices to the vagina, labia majora and minora, uterus, cervix, and ovarian veins in women with PGAD [5]. They further suggest that the presence of pelvic varices may induce local sensory neuropathy that is responsible for the sensations experienced by affected women [5]. Specifically, a sensory neuropathy of the dorsal nerve of the clitoris and/or pudendal nerve is suggested, as the authors were able to provoke both pre-orgasmic and orgasmic sensations in all of the patients studied by applying a relatively low amount of static mechanical pressure to the pudendal dermatome [5]. Evidence of PGAD secondary to pudendal neuropathy is further emphasized by a case report of a woman whose symptoms of spontaneous orgasms and persistent genital symptoms were temporarily relieved with a pudendal nerve block. Interestingly, a clitorodectomy in the same patient did not

Patient Informed Consent: Consent was obtained from the patient and is on file at The Centers for Vulvovaginal Disorders in Washington, DC.

give relief, thereby proving that she did not have pathology localized to the clitoris [6]. Recently, Tarlov cysts have also been suggested as a type of peripheral insult that can potentially contribute to the spectrum of PGAD pathology [7]. These perineurial lesions characteristically form on dorsal (sensory) roots in the S2 and S3 regions of the sacral spine and expand as a result of filling with cerebrospinal fluid; the subsequent compression of the sensory nerve roots can generate paresthesias and/or dysesthesias, and patients report similar symptoms of PGAD including genital, buttock, leg, and lower back pain [7]. In a study investigating the prevalence of Tarlov cysts in PGAD, Komisaruk and Lee demonstrated the presence of at least one such lesion in 12 out of 18 women (66.7%) who suffered from PGAD and previously underwent a diagnostic MRI [7]. They conclude that this high incidence strongly suggests that Tarlov cysts serve as a possible etiological factor underlying PGAD and advise physicians to rule out this cause in the absence of other pathology [7]. Psychological factors as a cause of PGAD have been less consistent. Some investigators have recognized increased rates of sexual abuse among patients with PGAD, while others have failed to replicate an increased incidence [3]. Authors that have identified this increased correlation speculate that a history of sexual trauma or abuse may result in negative associations with genital arousal [8]. Similarly, Leiblum et al. found that both women with PGAD who met all criteria for diagnosis and women who only met some criteria reported increased rates of sexual abuse. However, women who met all qualifying criteria were significantly more anxious, more likely to monitor their physical sensations, and more likely to endorse negative feelings about their genital sensations [9]. A subsequent hypothesis of this finding is that for certain women, psychological factors, namely, anxiety, can augment and sustain PGAD symptoms [9]. Regarding pharmacological causes, some case reports describe a temporal relationship between the onset of PGAD symptoms and the initiation or cessation of antidepressants or other mood stabilizers [2]. Specifically, out of 364 women surveyed who fit the criteria for PGAD, five clearly identified the start of their symptoms after the discontinuation of their selective serotonin reuptake inhibitor (SSRI)/serotonin-norepinephrine reuptake inhibitor and one after the initiation of her SSRI. It is hypothesized that these medications and the neurotransmitters that they affect have the potential to be stimulatory or

disinhibitory to central nervous system structures that control arousal [2]. Additionally, because genital sexual arousal is in part mediated by hypothalamic and limbic dopaminergic systems, some physicians have hypothesized that hyperactive dopamine release may play a significant role [10]. Other possible mechanisms include a return to baseline sexual function and increased attentiveness to genital sensations that had been previously suppressed by the medication [2].

In this report, we illustrate a case of PGAD resulting from a periclitoral mass, a rare type of peripheral insult.

Case Report

A 51-year-old gravida zero postmenopausal Caucasian woman presented to a referral center for vulvar disorders for a consultation with complaints of “heightened sexual desire” and a palpable, painful, periclitoral mass for 6 months. In addition to burning pain, she reported a “persistent sensation,” similar to sexual arousal. The patient reported that the mass enlarged with sexual stimulation, including intercourse and direct rubbing, and the sensation of constant arousal was unwanted, disturbing, and distressing. Furthermore, the sensation was present in the absence of sexual activity and was exacerbated by nonsexual stimuli. To relieve the sensation of persistent arousal, she had to masturbate or have intercourse many times per day. The patient acquired some relief when orgasm was achieved but never had complete resolution of symptoms. The referring gynecologist had performed a percutaneous drainage of the mass and had removed some serous fluid, but a hard subcutaneous nodule persisted. The patient reported moderate relief of her pain and arousal after drainage; however, her symptoms never fully resolved. Her medical, surgical, psychiatric, family, and social histories were noncontributory and she was not taking any medications.

Vulvar examination revealed a firm, tender 8 mm × 8 mm subcutaneous nodule approximately 1 cm lateral to the glans clitoris on the patient’s left side (Figure 1A). The remainder of the exam was normal and the patient’s complete blood count with differential was within normal limits. The patient was subsequently diagnosed with PGAD secondary to a periclitoral mass.

The mass was excised in an operating room using careful dissection through a 1-cm incision (Figure 1B). Histopathology of the mass revealed a papillary hidradenoma (hidradenoma

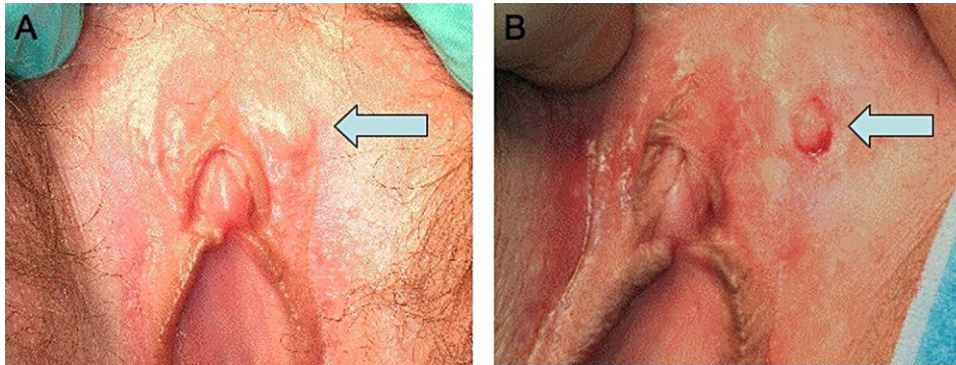


Figure 1 (A) Mass indicated at 1 o'clock position in relation to the patient's clitoris. (B) Mass after a 1-cm incision was made.

papilliferum) (Figure 2). Following the excision of the mass, the patient reported a gradual resolution of all pain and PGAD symptoms over several weeks, and she did not report any loss of clitoral or perineal sensation.

Discussion

PGAD is an enigmatic condition that likely results from multiple physical and/or psychological etiologies. Because it lacks a definitive pathogenesis, a streamlined method of systematic diagnosis and treatment has not yet been developed with certitude. Despite this, a collection of case reports and studies have guided management thus far. The woman described in this report presented with a typical history of a patient with PGAD as she was experiencing unrelenting physiological response characteristics of sexual arousal that were triggered

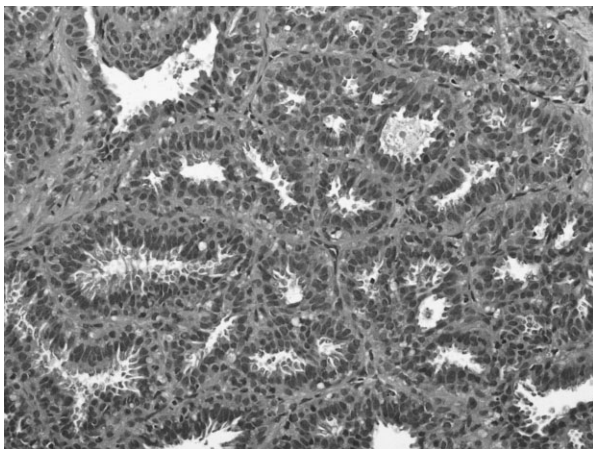


Figure 2 Photomicrograph of the papillary hidradenoma. It demonstrates complex papillary structures with fine fibrovascular cores covered by two layers of cells; a basal layer of flattened myoepithelial cells and a luminal layer of tall, bland appearing columnar cells with apocrine differentiation.

spontaneously or by nonsexual stimuli, which were subjectively intrusive and unwanted [1]. She had no prior history of psychotropic medication use and was otherwise healthy. Moreover, physical exam confirmed the patient's report of the presence of a palpable periclitoral mass. The temporary abatement of pain and arousal symptoms reported by the patient after percutaneous drainage of the mass was performed further emphasized that her PGAD symptoms were directly related to this peripheral insult.

The pudendal nerve originates from the S2–S4 segments of the sacral plexus and terminates into three branches [11]. The dorsal nerve of the clitoris is one branch that arises after the pudendal nerve exits the pudendal canal. It courses along the dorsal aspect of the clitoral body at the 11 and 1 o'clock positions [12] and is believed to carry only sensory fibers [11]. It logically follows that any mass that impinges on this nerve might lead to the sensory perception of clitoral pain or to persistent stimulation. While no direct physical or histological tests were performed to confirm a direct contiguity between the mass and the dorsal nerve of the clitoris, physical proximity was inferred based on the known anatomy of the nerve's course, the mass' location, and the patient's symptoms related to the mass.

Papillary hidradenomas are a rare, benign, cystic type of tumor that primarily occur in the vulva of Caucasian women. They typically present as solitary, slow-growing, painless nodules mostly on the labia majora or minora, in the sulcus between them, or in the perianal area [13]. A case series outlining the various histological and morphological patterns of these tumors indicate that those located on the clitoris are rare [14]. They are believed to arise from the anogenital mammary-like glands and exhibit both apocrine and eccrine differentiation [14,15]. Because of their benign and cystic nature, local surgical excision is

regarded as an adequate treatment [13,16]. As the patient's prior physician only drained the lesion, it is assumed that her symptoms returned once the hidradenoma refilled with serous fluid and the subsequent enlargement led to impingement upon the left dorsal nerve of the clitoris. Only after complete excision did her symptoms resolve.

Conclusion

This report emphasizes that PGAD is likely due to various etiologies, and as such no consistent model of management exists. While cases of peripheral neuropathies and other physical insults have been reported [3,5–7], incidences of a local mass leading to PGAD symptoms are not present in the literature. This case serves as the first report of a periclitoral mass causing PGAD. Peripheral causes of persistent sexual arousal should continue to be considered in the differential diagnosis of patients with PGAD, especially in patients without a history of psychotropic medication use. A targeted physical exam should be carefully performed as well to rule out the possibility of a local mass. Though rare, masses compressing on the dorsal nerve of the clitoris can be a potential cause, and complete excision can lead to symptom relief.

Acknowledgments

The authors would like to acknowledge Laurilee Roybal for her assistance in drafting the original abstract of this paper, as well as Dr. Scott Aesif and the George Washington University Hospital Department of Pathology for the preparation and interpretation of the histology specimen.

Corresponding Author: Sarah Bedell, BA, New York University School of Medicine, 334 East 26th Street, Apartment 17H2, New York, NY 10010, USA. Tel: 305-322-8612; E-mail: sb3158@nyumc.org

Conflict of Interest: All authors have no conflicts of interest to report.

Statement of Authorship

Category 1

(a) Conception and Design

Sarah Bedell; Lara Burrows; Andrew Todd Goldstein

(b) Acquisition of Data

Andrew Todd Goldstein

(c) Analysis and Interpretation of Data

Sarah Bedell; Lara Burrows; Andrew Todd Goldstein

Category 2

(a) Drafting the Article

Sarah Bedell; Andrew Todd Goldstein

(b) Revising It for Intellectual Content

Sarah Bedell; Andrew Todd Goldstein; Lara Burrows

Category 3

(a) Final Approval of the Completed Article

Sarah Bedell; Lara Burrows; Andrew Todd Goldstein

References

- 1 Basson R, Leiblum S, Brotto L, Derogatis L, Fourcroy J, Fugl-Meyer K, Graziottin A, Heiman JR, Laan E, Meston C, Schover L, van Lankveld J, Schultz WW. Revised definitions of women's sexual dysfunction. *J Sex Med* 2004;1:40–8.
- 2 Leiblum SR, Goldmeier D. Persistent genital arousal disorder in women: Case reports of association with anti-depressant usage and withdrawal. *J Sex Marital Ther* 2008;34:150–9.
- 3 Facelle TM, Sadeghi-Nejad H, Goldmeier D. Persistent genital arousal disorder: Characterization, etiology, and management. *J Sex Med* 2013;10:439–50.
- 4 Goldmeier D, Leiblum SR. Persistent genital arousal in women—A new syndrome entity. *Int J STD AIDS* 2006;17:215–6.
- 5 Waldinger MD, Venema PL, van Gils AP, Schweitzer DH. New insights into restless genital syndrome: Static mechanical hyperesthesia and neuropathy of the nervus dorsalis clitoridis. *J Sex Med* 2009;6:2778–87.
- 6 Waldinger MD, Venema PL, van Gils AP, Schutter EM, Schweitzer DH. Restless genital syndrome before and after clitoridectomy for spontaneous orgasms: A case report. *J Sex Med* 2010;7:1029–34.
- 7 Komisaruk BR, Lee HJ. Prevalence of sacral spinal (Tarlov) cysts in persistent genital arousal disorder. *J Sex Med* 2012;9:2047–56.
- 8 Leiblum S, Chivers M. Normal and persistent genital arousal in women: New perspectives. *J Sex Marital Ther* 2007;33:357–73.
- 9 Leiblum S, Seehuus M, Goldmeier D, Brown C. Psychological, medical, and pharmacological correlates of persistent genital arousal disorder. *J Sex Med* 2007;4:1358–66.
- 10 Korda JB, Pfaus JG, Goldstein I. Persistent genital arousal disorder: A case report in a woman with lifelong PGAD where serendipitous administration of varenicline tartrate resulted in symptomatic improvement. *J Sex Med* 2009;65:1479–86.
- 11 Vaze A, Goldman H, Jones JS, Rackley R, Vasavada S, Gustafson KJ. Determining the course of the dorsal nerve of the clitoris. *Urology* 2008;72:1040–3.
- 12 Ginger VA, Cold CJ, Yang CC. Surgical anatomy of the dorsal nerve of the clitoris. *Neurourol Urodyn* 2011;30:412–6.
- 13 Duhan N, Kalra R, Singh S, Rajotia N. Hidradenoma papilliferum of the vulva: Case report and review of literature. *Arch Gynecol Obstet* 2011;284:1015–7.
- 14 Scurry J, van der Putte SC, Pyman J, Chetty N, Szabo R. Mammary-like gland adenoma of the vulva: Review of 46 cases. *Pathology* 2009;41:372–8.
- 15 Meeker JH, Nenbecker RD, Helwig EB. Hidradenoma papilliferum. *Am J Clin Pathol* 1962;37:182–95.
- 16 Kaufmann T, Pawl NO, Soifer I, Greston WM, Kleiner GJ. Cystic papillary hidradenoma of the vulva: Case report and review of the literature. *Gynecol Oncol* 1987;26:240–5.