

# Fractionated Carbon Dioxide Laser for the Treatment of Vulvar Lichen Sclerosus

## A Randomized Controlled Trial

Leia Mitchell, MSc, Andrew T. Goldstein, MD, Debra Heller, MD, Theodora Mautz, BA, Chelsea Thorne, MSc, So Yeon Joyce Kong, PhD, MPH, Maria E. Sophocles, MD, Hillary Tolson, BA, and Jill M. Krampf, MD, MEd

**OBJECTIVE:** To estimate the efficacy of fractionated carbon dioxide (CO<sub>2</sub>) laser therapy for vulvar lichen sclerosus.

See related editorial on page 965.

From the Mercer University Physician Assistant Program, Atlanta, Georgia; the Centers for Vulvovaginal Disorders the Department of Obstetrics and Gynecology, George Washington University School of Medicine and Health Sciences, Washington, DC; the Department of Pathology and Laboratory Medicine and the Department Obstetrics, Gynecology, and Women's Health, Rutgers New Jersey Medical School, Newark, and Women's Healthcare of Princeton, Princeton, New Jersey; and Strategic Research, Laerdal Medical, Stavanger, Norway.

Partial funding for this study was obtained from the Gynecologic Cancer Research Foundation, a Maryland, USA 501(c)(3) non-profit corporation. Additional funding for this study was supplied by EL.En Group, Florence, Italy, the manufacturer of the laser used in this study. In addition, EL.En Group supplied the laser used in the study. EL.En Group had no role in the analysis and interpretation of data; in the writing of the report; or in the decision to submit the article for publication.

The authors thank Dr. Sarah Bedell, Dr. Sarah Cigna, Dr. Mollie Reiff, and Ms. Vaishnavi Govind for their help with data acquisition.

Andrew T. Goldstein, Leia Mitchell, and So Yeon Joyce Kong had full access to all the data in the study and take responsibility for the integrity of the data and the accuracy of the data analysis.

Each author has confirmed compliance with the journal's requirements for authorship.

Corresponding author: Andrew T. Goldstein, MD, the Centers for Vulvovaginal Disorders, Washington, DC; email: Obstetrics@yahoo.com.

### Financial Disclosure

Andrew T. Goldstein disclosed that he is President of the Gynecologic Cancer Research Foundation, a 501(c)(3) non-profit corporation, which provided partial funding for this study. He is a part-time employee of Dare Bioscience. He has received research funding from Dare BIOScience, SST, EndoCeutics, The Cellular Medicine Association, and Ipsen. He is a consultant for Ipsen, SST, and AMAG. Debra Heller received royalties for medical books, unrelated reimbursement/honorarium for giving CME talks at pathology meetings. Money was paid to her institution from the NIH and she received funds for medicolegal work. So Yeon Joyce Kong is an employee of Laerdal Medical, Stavanger, Norway. Maria Sophocles is on the speakers' bureau for Ducheny, DEKA, and Cynosure. The other authors did not report any potential conflicts of interest.

© 2021 by the American College of Obstetricians and Gynecologists. Published by Wolters Kluwer Health, Inc. All rights reserved. This is an open-access article distributed under the terms of the Creative Commons Attribution-Non Commercial-No Derivatives License 4.0 (CCBY-NC-ND), where it is permissible to download and share the work provided it is properly cited. The work cannot be changed in any way or used commercially without permission from the journal. ISSN: 0029-7844/21

**METHODS:** We conducted a prospective, double-blind, randomized, sham-controlled, trial conducted in a clinic specializing in vulvar disorders. The study participants were 40 women with active vulvar lichen sclerosus confirmed with biopsy who were abstaining from topical and systemic treatments for at least 4 weeks before enrollment. Women were randomized in a 1:1 ratio to receive either five sham laser treatments or five fractionated CO<sub>2</sub> treatments in a 24-week period. Study participants, treating clinicians, and the evaluating pathologist were blinded. The primary endpoint was the change in the histopathology scale score between pretreatment and posttreatment biopsies. We estimated 20 per group for 80% power to detect a 40% reduction in the histopathology scale score with up to 10% attrition. A secondary endpoint was the change in the validated CSS (Clinical Scoring System for Vulvar Lichen Sclerosus).

**RESULTS:** From November 2018 to June 2020, 40 women were randomized to participate in the trial, and 37 women (19 fractionated CO<sub>2</sub>, 18 sham) were included in an intention-to-treat (ITT) analysis. Three women were excluded from the ITT analysis because they did not have posttreatment biopsies and, therefore, a posttreatment histopathology scale score could not be obtained. There was a 0.20 reduction (improvement) in histopathology scale score from baseline in the active treatment group (95% CI -1.1, 0.80,  $P=.74$ ) and a 0.1 increase from baseline in the sham treatment group (95% CI -0.90, 1.0,  $P=.91$ ). The change in histopathology scale score between the active and sham arm was not statistically significant (95% CI -1.14, 1.06,  $P=.76$ ).

**CONCLUSION:** Fractionated CO<sub>2</sub> is not an effective monotherapy treatment for vulvar lichen sclerosus.

**CLINICAL TRIAL REGISTRATION:** ClinicalTrials.gov, NCT03665584.

**FUNDING SOURCE:** Additional funding for this study was supplied by EL.En Group, Florence, Italy, the manu-

manufacturer of the laser used in this study. In addition, El.En Group supplied the laser used in the study.

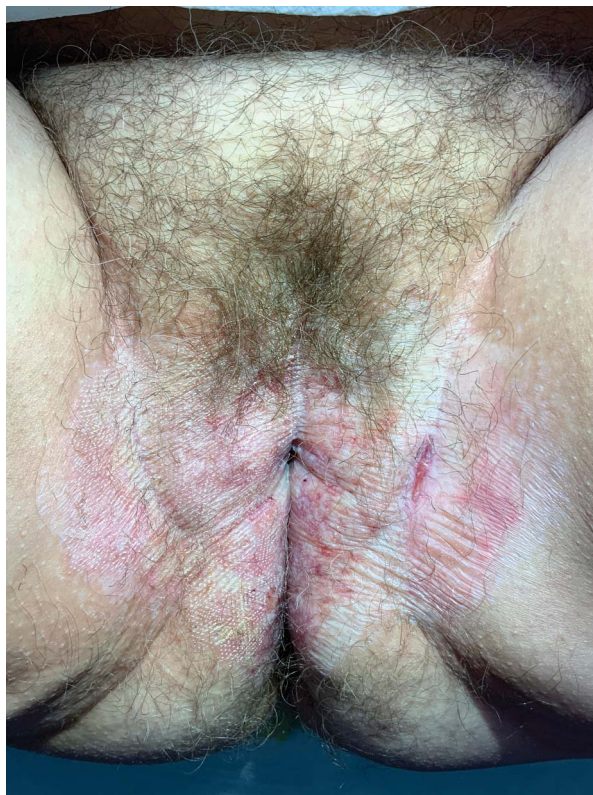(*Obstet Gynecol* 2021;00:1–9)

DOI: 10.1097/AOG.0000000000004409

Vulvar lichen sclerosis is a chronic cutaneous disorder affecting approximately one in 70 women.<sup>1</sup> Presenting symptoms may include intense pruritus, pain, burning, and severe dyspareunia. The typical lesions are white plaques and papules, often with areas of ecchymosis, excoriation, and ulceration, with destruction of the vulvar architecture. Four to seven percent of women with vulvar lichen sclerosis develop vulvar carcinoma.<sup>2</sup> The histopathologic changes of vulvar lichen sclerosis are distinctive, making biopsy a very useful diagnostic tool.<sup>3</sup> Although there is no known cure, the current gold standard treatment of topical ultrapotent corticosteroids help to resolve symptoms, prevent further vulvar scarring, reverse underlying histopathologic inflammation, and decrease the risk of malignant transformation.<sup>4–6</sup> Although treatment with topical corticosteroids is effective, these medications have the potential for serious local and systemic side effects, including dermal thinning, skin atrophy, superimposed infections, rebound dermatitis, and adrenal insufficiency.<sup>7</sup> Additionally, adequate treatment requires compliance with a regimen of long-term corticosteroid use. Even though the aforementioned side effects are uncommon, these concerns have prompted interest in alternative interventions.

Recently, fractionated carbon dioxide (CO<sub>2</sub>) laser has been proposed for the management of vulvar lichen sclerosis. This type of laser has a wavelength of 10,600 nm allowing a superficial microablative effect in soft tissues, as well as a pulsed beam, which protects tissues from possible damage due to overheating. The laser beam is delivered to the tissue in a fractional manner, creating small spots (150–200 micrometers) alternating parts of tissue treated and not treated (Fig. 1). The microablation stimulates remodeling of the connective tissue through the production of heat shock protein 47 and produces new collagen or fibroblasts and ground matrix.<sup>8</sup>

Multiple small, noncontrolled studies and case series have indicated fractionated CO<sub>2</sub> therapy as a promising treatment modality to treat vulvar lichen sclerosis.<sup>9–18</sup> These studies suggest that FxCO<sub>2</sub> treatment may stimulate protein synthesis, accelerate tissue reconstruction, and decrease lichenification. Furthermore, the clinical manifestations of lichen sclerosis, such as intense vulvar pruritus and burning, appear to improve. However, none of these studies



**Fig. 1.** A study participant with the classic features of lichen sclerosis, including lichenification, hypopigmentation, ecchymosis, fissures, and scarring. The participant's right side has been treated with the fractionated CO<sub>2</sub> laser, and the dots are visible.

Mitchell. Carbon Dioxide Laser for the Treatment of Vulvar Lichen Sclerosis. *Obstet Gynecol* 2021.

were blinded or placebo-controlled. In many of the studies, topical corticosteroids were used either concurrently or immediately before laser treatment. In addition, a number of these studies did not measure histologic changes before and after laser treatment and relied instead on subjective reporting and clinical observation. The current study evaluates the efficacy of fractionated CO<sub>2</sub> as a monotherapy treatment for vulvar lichen sclerosis in a randomized, blinded, sham-controlled trial.

## ROLE OF THE FUNDING SOURCE

The authors had access to relevant aggregated study data and other information (such as study protocol, analytic plan and report, validated data table, and clinical study report) required to understand and report research findings. The authors take responsibility for the presentation and publication of the research findings, have been fully involved at all stages of publication and presentation development,

and are willing to take public responsibility for all aspects of the work. All individuals included as authors and contributors who made substantial intellectual contributions to the research, data analysis, and publication or presentation development are listed appropriately. The role of the sponsor in the design, execution, analysis, reporting, and funding is fully disclosed. The authors' personal interests, financial or nonfinancial, relating to this research and its publication have been disclosed.

## METHODS

Institutional Review Board approval was obtained from Advarra IRB (Pro00024516) on March 1, 2018, and the study was listed on [www.clinicaltrials.gov](http://www.clinicaltrials.gov) (NCT03665584). There was no formal patient and public involvement in this research. Partial funding for this study was obtained from the Gynecologic Cancer Research Foundation, a nonprofit U.S. corporation. El.En Group, Florence, Italy, the manufacturer of the laser used in this study provided additional funding and supplied the laser used in the study. El. En Group had no role in the analysis and interpretation of data, in the writing of the report, or in the decision to submit the article for publication.

Women with a diagnosis of biopsy-proven active vulvar lichen sclerosis were recruited from a database of a center that specializes in the treatment of vulvar disorders. Women in the database were contacted by a clinical researcher by email or phone. At that time, the eligibility of each woman was determined using the inclusion and exclusion criteria. Women who were eligible were offered screening visits for the trial. Additionally, new patients with lichen sclerosis who presented to the center during the recruitment phase of this trial were offered inclusion in the trial if they met eligibility requirements. The study timeline consisted of a 4-week (minimum) washout period, a

2-week screening period, a 24-week treatment period, and an 8-week posttreatment period. For the washout period, participants were required to stop all topical corticosteroids, topical immunosuppressants, and any other medications used to treat vulvar lichen sclerosis. In the screening period, a 4-mm punch skin biopsy was collected from each patient to confirm the diagnosis of active lichen sclerosis and to rule out the diagnoses of lichen planus, psoriasis, and vulvar intraepithelial neoplasia. A vulvoscopy was performed at the screening visit and after the 24-week treatment period to rule out vulvar carcinoma or vulvar intraepithelial neoplasia. All eligible patients were randomized to receive either five sham treatments (FxC<sub>2</sub> with very minimal laser energy emitted) or five active treatments of FxC<sub>2</sub> (with laser energy emitted). Using photo documentation as a guide, a repeat biopsy was performed adjacent to the original biopsy site 8 weeks after the final treatment.

Randomization was performed by a research assistant who input all study variables into the website [www.sealedenvelope.com](http://www.sealedenvelope.com). Randomization was a 1:1 ratio of active to sham treatment.

The FxC<sub>2</sub> treatment was performed at baseline and then repeated at 4 weeks intervals for a total of five treatments, using a protocol recommended by the laser's manufacturer (Table 1). The laser's settings were set by a research associate and these setting were obscured so that the treating physician could not see them. The sham treatment was intentionally designed to deliver a very small amount of laser energy to this tissue. There is a patient awareness shared on vulvar lichen sclerosis social media groups that fractionated CO<sub>2</sub> produces visible spots on the skin and creates smoke and odor from skin vaporization. The amount of energy used in the sham group was enough to create the spots, smoke, and odor so that both the

**Table 1. Power Setting for Fractionated Carbon Dioxide Treatments**

	Treatment (n)	Power (watts)	Dwell Time (microseconds)	Spacing (micrometers)	Smartstack (n)
Active treatment arm	1	18	800	1,200	1
	2	20	900	1,100	1
	3	22	1,000	1,000	1
	4	24	1,000	1,000	1
	5	26	1,000	1,000	1
Sham treatment arm	1	4	400	1,500	1
	2	4	400	1,500	1
	3	4	400	1,500	1
	4	4	400	1,500	1
	5	4	400	1,500	1

patients and investigator remained blinded, but not strong enough to affect the pathologic process.

The primary efficacy endpoint was improvement in the histopathologic changes of vulvar lichen sclerosus in biopsy specimens obtained during the screening period and after the 24-week treatment period. The histopathologic changes were evaluated by a blinded expert gynecologic pathologist (D.H.), who quantified the severity of the changes on a 0- to 6-point histopathology scale.<sup>19</sup> This histopathology scale quantifies the loss of rete pegs, the amount of dermal homogenization, and the amount of chronic inflammation. A secondary endpoint was the change from baseline in the CSS (Clinical Scoring System for Vulvar Lichen Sclerosus), a validated instrument that assesses both an investigator's impression of the severity of disease and a patient's impression of the severity of her symptoms.<sup>20</sup> The patients' subjective section of the CSS is scored from 0 to 40 and is the total of the four domains: pruritus, soreness, burning, and dyspareunia. The clinicians' objective section of the CSS is scored from 0 to 12 and is the sum of six domains: fissures, erosions, hyperkeratosis, agglutination, stenosis, and atrophy.

A sample size calculation was performed before the onset of the study. Because lichen sclerosus is a premalignant condition that causes permanent changes in vulvar anatomy, a minimal improvement in the histopathology scale score would not be clinically significant. As such, it was decided that the study should be powered to show a 40% reduction in the histopathology scale score from baseline (pre) to completion of treatment (post). Therefore, assuming a 40% reduction in histopathology scale score with mean change of  $-0.40$  in the active treatment group and  $-0.24$  in the sham treatment group, the mean difference of  $-0.16$  between two group with SDs of 0.17 for both groups, and a sample size of 36 (18 per each group) would provide 80% power with a two-sided significance level of 0.05. Considering an estimated 10% dropout rate and 30% would be ineligible, a total of 50 participants was estimated to be recruited for this trial.

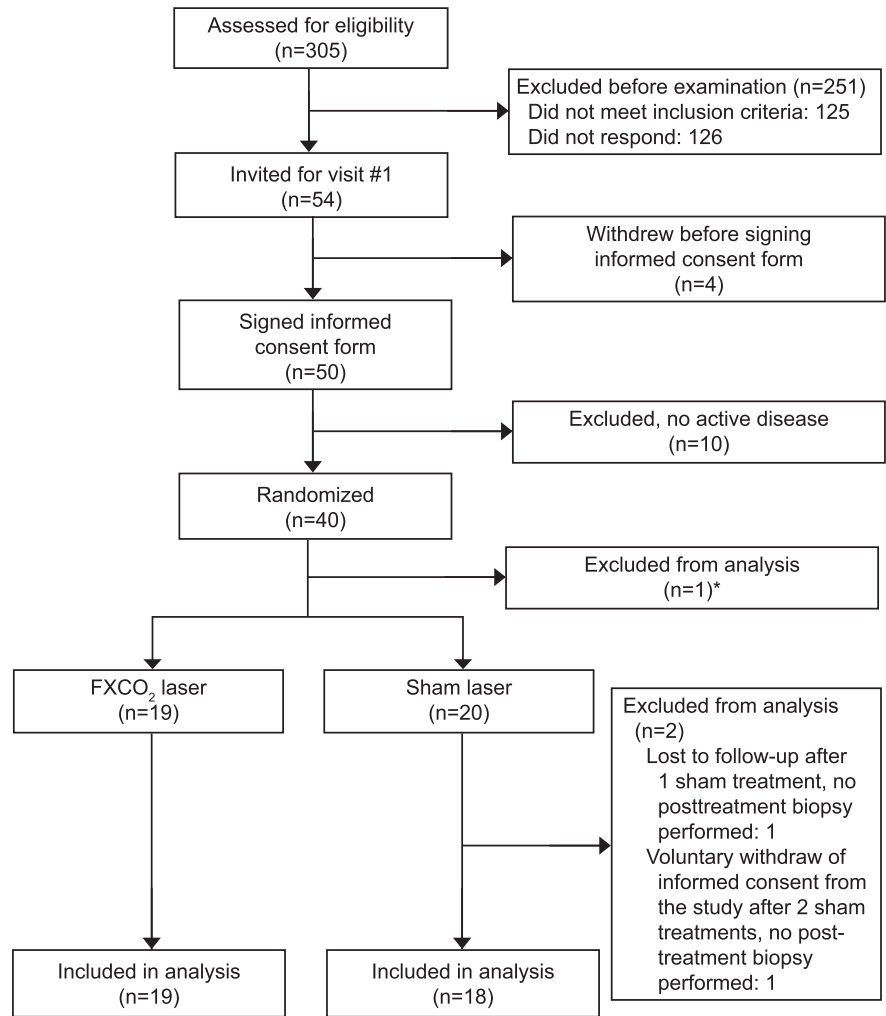
Duration of symptoms was determined by the study coordinator who queried each participant as to when their symptoms started. For those participants who were asymptomatic at the time of diagnosis, the length of time since histopathologic confirmation of lichen sclerosus was used as the duration of symptoms. The analysis of study outcomes was based on generalized linear models for histopathology scale score, patient CSS, and physician CSS. Changes over time in the histopathology scale scores and CSS

(differences between second (for histopathology scale scores) and third (for patient CSS and physician CSS) from the baseline) between treatment and control groups were also assessed (difference-in-difference method). Study outcomes were modeled with regression models using SAS procedure PROC GLM. Results of the PROC GLM models are reported as means and the 95% CIs. All statistical analysis was performed using SAS 9.4.

## RESULTS

This study was conducted between November 2018 and June 2020. A total of 305 women with vulvar lichen sclerosus from a patient database were screened for eligibility. As shown in Figure 2, 50 women met initial inclusion criteria and agreed to participate in the study. Ten women did not have active disease on examination or pretreatment biopsy and were, therefore, excluded before treatment. Forty women were randomized: 20 were assigned to receive FxCO<sub>2</sub> laser and 20 were assigned the sham laser. We performed an intention-to-treat (ITT) analysis for all women enrolled in the study and a per protocol analysis of the women who completed the entire study. Three women were not included in the ITT analysis because they did not have posttreatment biopsies at the end of their participation in the trial. One participant in the sham arm withdrew consent after two treatments because of a severe exacerbation of her symptoms and did not consent to an early termination biopsy, one participant in the sham arm was lost to follow-up after only one treatment, and one participant who was randomized to the active treatment arm withdrew voluntarily before receiving any treatments because of a severe exacerbation of symptoms after stopping steroids. Two additional women were excluded from the per protocol analysis because they had missed two or more treatments because of coronavirus disease 2019 (COVID-19) travel restrictions and office closures and, therefore, they did not complete the entire trial. As such, 37 women were included in the ITT analysis and 35 women were included in the per protocol analysis (Table 2).

The histopathology scale ranges from 0 to 6. In the ITT analysis, shown in Table 3, the histopathology scale score before treatment in the sham group was 4.3 and the histopathology scale score in the fractionated CO<sub>2</sub> treatment group was 4.2 ( $P=.89$ ). There was a 0.2 reduction (improvement) in histopathology scale score from baseline in the active treatment group (95% CI  $-1.1, 0.8, P=.74$ ) and a 0.1 increase from baseline in the sham treatment group (95% CI  $-0.90, 1.0, P=.91$ ). The change in histopathology scale score



**Fig. 2.** CONSORT (Consolidated Standards of Reporting Trials) diagram.

Mitchell. Carbon Dioxide Laser for the Treatment of Vulvar Lichen Sclerosus. *Obstet Gynecol* 2021.

between the active and sham arms was not statistically significant ( $-0.2$ ; 95% CI  $-1.14, 1.06, P=.76$ ). In the per protocol analysis, there was a 0.10 reduction (improvement) in histopathology scale score from baseline in the per protocol active treatment group (95% CI

$-1.0, 0.90, P=.90$ ) and a 0.1 increase from baseline in the per protocol sham treatment group (95% CI  $-0.9, 1.1, P=.91$ ). The change in histopathology scale score between the active and sham arms was not statistically significant ( $-0.2$ ; 95% CI  $-1.14, 1.06, P=.80$ ).

**Table 2. Demographics of the Study Participants**

Variables	Treatment		
	All (n=35)	Active (n=17)	Sham (n=18)
Age (y)	59 (51–64)	59 (55–64)	59 (50–65)
Race			
Black	1 (3)	1 (6)	0 (0)
White	31 (89)	14 (82)	17 (94)
Other*	3 (9)	2 (12)	1 (6)
Years with symptoms	8 (4–13)	5 (2–10)	10 (5–13)

Data are median (interquartile range) or n (%).

P-values based on Wilcoxon-rank sum test for age and years with symptoms and Fisher exact test for race.

\* Other includes Spanish, Brazilian, and Hispanic.

**Table 3. Results of the Primary and Secondary Outcome Measures**

Outcome	Treatment	Per Protocol			Intention-To-Treat		
		Pretreatment	Posttreatment	Post-Pre Treatment	Pretreatment	Posttreatment	Post-Pre Treatment
Primary outcome		Total n=35; Active n=17; Sham n=18			Total N=37; Active n=19; Sham n=18		
Biopsy HS score	Active treatment	4.4 (3.7–5.1)	4.3 (3.6–5.0)	-0.1 (-1.0 to 0.9) <i>P</i> =.90	4.2 (3.5–4.9)	4.1 (3.4–4.7)	-0.2 (-1.1 to 0.8) <i>P</i> =.74
	Sham treatment	4.3 (3.6–5.0)	4.3 (3.7–5.0)	0.1 (-0.9 to 1.1) <i>P</i> =.91	4.3 (3.6–5.0)	4.3 (3.6–5.0)	0.1 (-0.9 to 1.0) <i>P</i> =.91
	<i>P</i> *	<i>P</i> =.78	<i>P</i> =.94	0.80	<i>P</i> =.89	<i>P</i> =.56	<i>P</i> =.76
Secondary outcomes		Total n=35; Active n=17; Sham n=18			Pretreatment: Total N=37; Active n=19; Sham n=18 Posttreatment: Total n=35; Active n=18; Sham n=18		
Patients' CSS	Active treatment	24.3 (19.8–28.8)	17.5 (13.0–22.0)	-6.8 (-13.2 to -0.4) <i>P</i> =.04	24.7 (20.5–29.0)	17.6 (13.2–22.0)	-7.1 (-13.2 to -1.0) <i>P</i> =.02
	Sham treatment	25.1 (20.7–29.5)	20.3 (15.9–24.7)	-4.8 (-11.1 to 1.4) <i>P</i> =.13	25.1 (20.8–29.5)	20.3 (16.0–24.7)	-4.8 (-9.5 to 0.2) <i>P</i> =.04
	<i>P</i> *	<i>P</i> =.79	<i>P</i> =.37	<i>P</i> =.66	<i>P</i> =.90	<i>P</i> =.39	<i>P</i> =.60
Providers' CSS	Active treatment	7.5 (6.5–8.6)	8.4 (7.3–9.4)	0.8 (-0.7 to 2.3) <i>P</i> =.27	7.8 (6.8–8.8)	8.4 (7.4–9.5)	0.7 (-0.8 to 2.1) <i>P</i> =.36
	Sham treatment	9.1 (8.0–10.1)	8.8 (7.8–9.8)	-0.3 (-1.7 to 1.2) <i>P</i> =.70	9.1 (8.0–10.1)	8.8 (7.8–9.8)	-0.3 (-1.7 to 1.2) <i>P</i> =.70
	<i>P</i> *	<i>P</i> =.04	<i>P</i> =.56	0.29	<i>P</i> =.08	<i>P</i> =.65	<i>P</i> =.36

HS, histopathology scale; CSS, Clinical Scoring System for Vulvar Lichen Sclerosus.

Data are mean (95% CI) unless otherwise specified.

\* *P* for difference between groups.

For the secondary endpoints of the CSS, in the ITT population there was a 7.10-point reduction (improvement) in the patients' CSS from baseline in the active arm (95% CI -13.2, -1.1, *P*=.02) and a 4.80-point reduction in the sham treatment group (95% CI -9.50, -0.20, *P*=.04), but the difference between the active and sham treatment groups was not statistically significant *P*=.60. In the physicians' 12 point CSS, there was a 0.70 increase (worsening) in the active (95% CI -0.80, 2.1, *P*=.36) and a 0.30 reduction in the sham treatment group (95% CI -1.7, 1.2, *P*=.70). Neither treatment group had a statistically significant change in the physicians' CSS from baseline to the end of the study. Additionally, the difference in the physicians' CSS between the two treatment arms was not statistically significant (*P*=.36). The results of the CSS in the per protocol population were similar to the ITT population and can be found on Table 3. Other than complaints of transient, mild discomfort, no adverse events were reported.

## DISCUSSION

This study showed that there was no meaningful improvement in the histopathologic changes of vulvar lichen sclerosus with fractionated CO<sub>2</sub> laser therapy

compared with sham treatment, indicating that fractionated CO<sub>2</sub> is not an effective monotherapy for vulvar lichen sclerosus. An additional significant finding is that women in both the active treatment arm and sham treatment arm experienced a statistically significant improvement in symptoms of vulvar lichen sclerosus, illustrating a large placebo effect and highlighting the need for randomized, controlled trials to obtain meaningful data for the treatment of vulvar lichen sclerosus.

In many studies, fractionated CO<sub>2</sub> has been shown to be an effective treatment for genitourinary syndrome of menopause (formerly known as vulvovaginal atrophy). Specifically, randomized, controlled studies of fractionated CO<sub>2</sub> have shown to significantly improve the symptoms of genitourinary syndrome of menopause, such as vaginal dryness and dyspareunia.<sup>21,22</sup> Additionally, fractionated CO<sub>2</sub> has been shown to improve the histopathologic changes of genitourinary syndrome of menopause, including increasing submucosal vascularity, collagen deposits and elastin fibers.<sup>23</sup> However, in the vast majority of cases there is only mild inflammatory changes associated with genitourinary syndrome of menopause. In contrast, the inflammatory process in vulvar lichen sclerosus, which is most likely of autoimmune

etiology, is incredibly robust. The intense inflammation process can cause severe induration, lichenification, fissures, erosions, severe scarring, and malignant transformation. Our study demonstrated that fractionated CO<sub>2</sub> does not have the ability to reverse the intense inflammation of vulvar lichen sclerosis.

The results of our study contrast with several studies that have shown fractionated CO<sub>2</sub> to be beneficial for women with vulvar lichen sclerosis. However, there are significant methodologic flaws in previous studies that must be noted. Pagano et al performed a prospective, nonrandomized, noncontrolled, nonblinded study of 40 women with vulvar lichen sclerosis treated with fractionated CO<sub>2</sub>.<sup>15</sup> Thirty-seven of the 40 women also were treated for genitourinary syndrome of menopause with the laser. They reported a statistically significant improvement in the patients' symptoms of pruritis, dryness, and dyspareunia, but it is unclear whether the improvement in symptoms was related to treatment of vulvar lichen sclerosis or genitourinary syndrome of menopause, or both. Additionally, it is possible that this improvement was due entirely to placebo effect, as our study also showed that women who received the sham treatment had a statistically significant improvement in subjective symptoms as measured by the CSS. Another study by Balchander and Nyirjesy was a retrospective study of 40 women with vulvar lichen sclerosis treated with fractionated CO<sub>2</sub>. As in the Pagano study, the majority of participants were also treated for genitourinary syndrome of menopause, in this study with both fractionated CO<sub>2</sub> and topical estradiol. Additionally, 38 of the 40 remained on corticosteroids throughout the treatment period.<sup>16</sup> It is unclear whether the improvement in vaginal pain, itching, dyspareunia, and dysuria that they found was related to treatment of the vulvar lichen sclerosis, genitourinary syndrome of menopause, or both, or was due to placebo effect, or the effects of the corticosteroid and estradiol or both. Lastly, Baggish published a retrospective case series of 27 women with biopsy-proven lichen sclerosis treated with three to four treatments of fractionated CO<sub>2</sub>, with power settings similar to our study. He describes that, "visible improvement of the vulvar skin was seen in 26/27 patients, while 24/27 women have had no further itching or any sort of vulvar discomfort or pain."<sup>17</sup> Unfortunately, there was no independent corroboration of these observations nor any objective data such as post-treatment histopathology or an evaluation of post-treatment photos by an independent clinician. It should be noted that, in all of the studies described above, the patients paid for their treatments—typically

\$500 or more per treatment. As such, there is a concern for confirmation bias in the form of elevation of commitment bias for the investigators and cognitive dissonance bias of the patients in all of these studies.

Nonablative neodymium:yttrium aluminum garnet laser treatment has also been studied for vulvar lichen sclerosis. Bizjak-Ogrinc and colleagues conducted a randomized, nonblinded study that compared 20 women who used corticosteroids and had three fractional neodymium:yttrium aluminum garnet laser treatments to 20 women who used corticosteroids alone. Pretreatment and posttreatment biopsies were obtained and showed no statistical difference in inflammation between groups.<sup>18</sup>

In contrast to the aforementioned studies that have examined fractionated CO<sub>2</sub> for vulvar lichen sclerosis, our study is prospective, randomized, double-blind, and sham controlled. To ensure blinding, the sham treatment we chose was designed to deliver a very small amount of laser energy to this tissue to produce visible spots on the skin and creates smoke and odor from skin vaporization, but not strong enough to affect the pathologic process. Blinding is especially important because, as our results demonstrated, there is a very strong placebo effect in this type of study, evidenced by a statically significant increase in the patients' subjective symptom improvement in the sham treatment arm.

Another strength of our study is use of underlying histopathologic changes as the primary endpoint. The underlying inflammation in vulvar lichen sclerosis causes significant morbidity beyond subjective symptoms, including both vulval scarring and a significant risk of malignant transformation. As such, any treatment that only improves symptoms, but does not reverse underlying histopathologic changes is inadequate. It is important to emphasize that ultrapotent corticosteroids, the current gold standard treatment for, do reverse the histopathologic changes of vulvar lichen sclerosis, thereby reducing additional scarring and decreasing the risk of malignant transformation. Because ultrapotent corticosteroids are readily available, any new treatment for vulvar lichen sclerosis must show also reduction in underlying histopathologic changes. As such, the U.S. Food and Drug Administration has recently indicated that improvement in histopathologic changes must be the primary endpoint in any investigational new drug application. The use of the CSS, a validated tool designed specifically for vulvar lichen sclerosis, as a secondary endpoint is also a strength of the study. As it measures both the patient's subjective symptoms and objective clinician finding, if it is used in a blinded study,

meaningful data regarding improvement or progression of vulvar lichen sclerosis can be obtained.

Another strength of our study was the elimination of confounding variables. Specifically, there was a treatment washout period and active vulvar lichen sclerosis was confirmed by histopathology at the onset of the study in all study participants. Additionally, no fractionated CO<sub>2</sub> treatments were administered for the treatment of genitourinary syndrome of menopause during the study. The specific energy settings used in the study were optimized for the treatment for vulvar lichen sclerosis. Additionally, the number of treatments in this study (five) was standardized and of a significant quantity to ensure that efficacy could be demonstrated.

One weakness of this study was its relatively small sample size. However, an a priori sample size calculation determined that the selected sample was large enough to demonstrate a clinically meaningful difference in the primary endpoint (histopathologic changes of vulvar lichen sclerosis). An additional limitation of this study is that rater bias was potentially introduced as several different (blinded) clinicians participated in scoring the physicians' section of the CSS. An additional weakness was the relatively racially homogenous population, which may affect applicability in non-White populations of women because the effects of fractionated laser treatments on different Fitzpatrick skin types can be variable.<sup>24</sup>

Another weakness is the variability in patient population in regard to prior treatments for lichen sclerosis. Some of the women had never received treatment for their vulvar lichen sclerosis, others had used corticosteroids but were noncompliant with treatment regimens (or had adverse reactions to steroids), and others had used corticosteroids but continued to be symptomatic. However, as mentioned in the Methods section, all women had to have active vulvar lichen sclerosis on biopsy to qualify for participation in the treatment phase of the trial and 10 women were excluded after they had signed informed consent because their biopsies did not confirm active vulvar lichen sclerosis.

Despite previously optimistic results in well-designed clinical trials of fractionated CO<sub>2</sub> for genitourinary syndrome of menopause, and in noncontrolled case series for vulvar lichen sclerosis, our study failed to show any significant benefit of monotherapy of fractionated CO<sub>2</sub> for vulvar lichen sclerosis. There may be a role for fractionated CO<sub>2</sub> as an adjuvant therapy along with topical ultrapotent corticosteroids in vulvar lichen sclerosis. To adequately study this, however, will require additional well-

designed studies that include a sham-placebo arm, as our study demonstrated a large placebo effect.

## REFERENCES

1. Goldstein AT, Marinoff SC, Christopher K, Srodon M. Prevalence of vulvar lichen sclerosis in a general gynecology practice. *J Reprod Med* 2005;50:477-80.
2. Cooper SM, Gao XH, Powell JJ, Wojnarowska F. Does treatment of vulvar lichen sclerosis influence its prognosis? *Arch Dermatol* 2004;140:702-6. doi: 10.1001/archderm.140.6.702
3. Tran DA, Xiaohui T, Macri CJ, Goldstein AT, Fu SW. Lichen sclerosis: an autoimmunopathogenic and genomic enigma with emerging genetic and immune targets. *Int J Biol Sci* 2019;15:1429-39. doi: 10.7150/ijbs.34613
4. Lewis FM, Tatnall FM, Velangi SS, Bunker CB, Kumar A, Brackenbury F, et al. British Association of Dermatologists guidelines for the management of lichen sclerosis, 2018. *Br J Dermatol* 2018;178:839-53. doi: 10.1111/bjd.16241
5. Kirtschig G, Becker K, Güntherth A, Jasaitiene D, Cooper S, Chi CC, et al. Evidence-based (S3) guideline on (anogenital) lichen sclerosis. *J Eur Acad Dermatol Venereol* 2015;29:e1-43.
6. Lee A, Bradford J, Fischer G. Long-term management of adult vulvar lichen sclerosis: a prospective cohort study of 507 women. *JAMA Dermatol* 2015;151:1061-7. doi: 10.1001/jamadermatol.2015.0643
7. Furue M, Terao H, Rikihisa W, Urabe K, Kinukawa N, Nose Y, et al. Clinical dose and adverse effects of topical steroids in daily management of atopic dermatitis. *Br J Dermatol* 2003;148:128-33. doi: 10.1046/j.1365-2133.2003.04934.x
8. Hantash BM, Bedi VP, Struck SK, Chan KF. Immunohistochemical evaluation of the heat shock response to nonablative fractional resurfacing. *JBO* 2010;15:068002. doi: 10.1117/1.3526355
9. Ferrara F, Messori S, Abbenante D, Patrizi A, Bardazzi F. Fractional CO<sub>2</sub> laser therapy of lichen sclerosis in males: a new therapeutic opportunity? *J Dermatol Treat* 2020 Jul 20 [Epub ahead of print]. doi: 10.1080/09546634.2020.1793886
10. Gómez-Friero M, Laynez-Herrero E. Use of Er:YAG laser in the treatment of vulvar lichen sclerosis. *Int J Women's Dermatol* 2019;5:340-4. doi: 10.1016/j.ijwd.2019.05.007
11. Hobson JG, Ibrahim SF, Mercurio MG. Recalcitrant vulvar lichen sclerosis treated with erbium YAG laser. *JAMA Dermatol* 2019;155:254-6. doi: 10.1001/jamadermatol.2018.4461
12. Lee A, Lim A, Fischer G. Fractional carbon dioxide laser in recalcitrant vulval lichen sclerosis. *Australas J Dermatol* 2016; 57:39-43. doi: 10.1111/ajd.12305
13. Mendieta-Eckert M, Ocerin-Guerra I, Landa-Gundin N. Lichen sclerosis et atrophicus in a surgical scar treated with fractional laser. *J Cosmet Laser Ther* 2017;19:106-8. doi: 10.1080/14764172.2016.1262955
14. Mendieta-Eckert M, Torrontegui Bilbao J, Zabalza Estévez I, Landa Gundin N. Treatment of vulvar lichen sclerosis et atrophicus with fractional carbon dioxide laser therapy: a report of 4 cases [published online ahead of print, 2020 Jul 14 [in English, Spanish]]. *Actas Dermosifiliogr* 2021;112:85-8. doi: 10.1016/j.ad.2019.03.021
15. Pagano T, Conforti A, Buonfantino C, Schettini F, Vallone R, Gallo A, et al. Effect of rescue fractional microablative CO<sub>2</sub> laser on symptoms and sexual dysfunction in women affected by vulvar lichen sclerosis resistant to long-term use of topical corticosteroid: a prospective longitudinal study. *Menopause* 2020;27:418-22. doi: 10.1097/GME.0000000000001482



16. Balchander D, Nyirjesy P. Fractionated CO2 laser as therapy in recalcitrant lichen sclerosus. *J Lower Genital Tract Dis* 2020;24:225–8. doi: 10.1097/LGT.0000000000000512
17. Baggish MS. Fractional CO2 laser treatment for vaginal atrophy and vulvar lichen sclerosus. *J Gynecol Surg* 2016;32:309–17. doi: 10.1089/gyn.2016.0099
18. Bizjak Ogrinc U, Senčar S, Luzar B, Lukanović A. Efficacy of non-ablative laser therapy for lichen sclerosus: a randomized controlled trial. *J Obstet Gynaecol Can* 2019;41:1717–25. doi: 10.1016/j.jogc.2019.01.023
19. Goldstein AT, Mitchell L, Govind V, Heller D. A randomized double-blind placebo-controlled trial of autologous platelet-rich plasma intradermal injections for the treatment of vulvar lichen sclerosus. *J Am Acad Dermatol* 2019;80:1788–9. doi: 10.1016/j.jaad.2018.12.060
20. Günthert AR, Duclos K, Jahns BG, Krause E, Amann E, Limmacher A, et al. Clinical scoring system for vulvar lichen sclerosus [published erratum appears in *J Sex Med* 2020;17:1825]. *J Sex Med* 2012;9:2342–50. doi: 10.1111/j.1743-6109.2012.02814.x
21. Ruanphoo P, Bunyavejchevin S. Treatment for vaginal atrophy using microablative fractional CO2 laser: a randomized double-blinded sham-controlled trial. *Menopause* 2020;27:858–63. doi: 10.1097/GME.0000000000001542
22. Cruz VL, Steiner ML, Pompei LM, Strufaldi R, Fonseca FL, Santiago LH, et al. Randomized, double-blind, placebo-controlled clinical trial for evaluating the efficacy of fractional CO2 laser compared with topical estriol in the treatment of vaginal atrophy in postmenopausal women. *Menopause* 2018;25:21–8. doi: 10.1097/GME.0000000000000955
23. Samuels JB, Garcia MA. Treatment to external labia and vaginal canal with CO2 laser for symptoms of vulvovaginal atrophy in postmenopausal women. *Aesthet Surg J* 2019;39:83–93. doi: 10.1093/asj/sjy087
24. Wong CSM, Chan MWM, Shek SYN, Yeung CK, Chan HHL. Fractional 1064 nm picosecond laser in treatment of melasma and skin rejuvenation in Asians, a prospective study. *Lasers Surg Med* 2021 Feb 5 [Epub ahead of print]. doi: 10.1002/lsm.23382

#### PEER REVIEW HISTORY

Received January 1, 2021. Received in revised form March 6, 2021. Accepted March 11, 2021. Peer reviews and author correspondence are available at <http://links.lww.com/AOG/C310>.

## New Article Type – Research Letter

The Research Letter is a concise, focused report of original research (including pre-clinical research, subanalyses or updates of previously published research, small studies, or pilot studies). If you are interested in submitting a Research Letter article, please see our Instructions for Authors.

*rev 2/2020*